

Clinical, Cytogenetic, and Molecular characterization of Disorders of Sexual Development (DSD) in Sudan

Samia Mahdi Ahmed¹ ✉, Imad Fadl-Elmula²

1. Department of Medical Laboratories, College of Applied Medical Sciences, Taibah University, Almadeena Almonawara, Saudi Arabia

2. Department of Clinical Genetics, Nahda College, Khartoum-Sudan

✉ Corresponding author email: smmohammed@taibahu.edu.sa

Genomics and Applied Biology, 2015, Vol.6, No.8 doi: 10.5376/gab.2015.06.0008

Received: 27 Sep., 2015

Accepted: 22 Nov., 2015

Published: 14 Jan, 2016

© 2015 Samia et al., This is an open access article published under the terms of the Creative Commons Attribution License, which permits unrestricted use, distribution, and reproduction in any medium, provided the original work is properly cited.

Preferred citation for this article:

Samia Mahdi Ahmed, and Imad Fadl-Elmula., 2015, Clinical, Cytogenetic, and Molecular characterization of Disorders of Sexual Development (DSD) in Sudan, Genomics and Applied Biology, Vol.6, No.8: 1-6 (doi:10.5376/gab.2015.06.0008)

Abstract Sex determination is defined as a genetic events that lead to male or female gonadal-development, whereas sexual differentiation is the subsequent steps leading to functional sexuality and secondary sexual characteristics. DSD have an estimated incidence of 0.1 to 0.5% of live births. It presents in several forms e.g., male and female pseudohermaphroditism, gonadaldysgenesis, and true hermaphroditism.

Aims

The present study aimed to explore and characterize cytogenetics, molecular alterations, hormonal profile, and clinical aspects of different types of DSD in Sudan for the first time.

Methods

The study comprised 70 patients, of which 18 raised as males, and 52 as females. Medical history, physical examination, culturing of lymphocytes, chromosomal analysis, PCR analysis for SRY gene, hormonal profile, pelvic ultrasound, laparoscopic examination (when required), histopathology, and psychological assessment were done.

Results

The vast majority of patients (40%) were adults ≥ 17 -year-old, followed by patients ≤ 2 year-old (33%). Although, 50% of the patients were referred due to genital ambiguity, other cause including primary amenorrhea, failure to thrive, and short stature were reported. Of the 70 patients only 13 patients (19%) were satisfied with their sex of rearing, 5 patients (6%) were not satisfied, 16 patients (23%) could not decide, and 36 patients (51%) were children. Female genital mutilation was performed in almost all adult patients raised as female including those diagnosed as Male pseudohermaphrodites. The analysis showed 23 patients were diagnosed as male pseudohermaphrodites, 2 as testicular feminization syndrome, 14 as complete gonadal dysgenesis, 8 as female pseudohermaphrodites, 6 as true hermaphrodites, 1 as Smith-Lemli-Opitz syndrome, one case of Down syndrome, and 15 patients were under controversial till the end of the study.

Conclusion

Based on the study conclusion one may concludes that multidisciplinary approach remains the best strategy for diagnosis and management of such cases. Labor-attending staff should be well trained to avoid sex assignment errors. Female genital mutation, if performed in DSD, ends the chance of prepuberty diagnosis and complicates the sex-reassignment constructive surgery.

Keywords Disorders of sexual development; intersex

Introduction

DSD have an estimated incidence of 0.1 to 0.5% of live births; and may present in several forms including male and female pseudohermaphroditism, gonadal dysgenesis, and true hermaphroditism (1).

In recent publications proposed classifications are 46,XY DSD, 46,XX DSD and sex chromosome DSD (2). Diagnosis and management of such patients remains controversial challenge that requires highly

specialized, multidisciplinary, and well trained team (3). The work-up of patients with DSD comprise the defining of their genetic (chromosomal), gonadal (hormonal), phenotypic, and psychological aspects (4). The real magnitude of DSD is not yet fully known in Sudan, but hospitals registries indicate clear increased in the number of new cases.

The present study aimed to explore and characterize the cytogenetic, molecular alterations, hormonal

profile, imaging, and clinical aspects of different types of intersex in Sudanese patients. It aimed also to introduce cytogenetic and molecular techniques in clinical diagnosis of patients with ambiguous genitalia, and to initiate a multidisciplinary working group that can shoulder the responsibility of the diagnosis, management, and postoperative care of intersex patients in Sudan.

Materials and methods

Patients

Seventy patients were referred with provisional diagnosis of DSD from hospitals and/or private clinics of different geographical regions in Sudan during the period of January 2010 to March 2012. Of the 70 patients, 18 were assigned at birth as males; their age ranged between 49 days and 32 years, while 52 were raised and hence presented as females; their age ranged between 7 days and 34 years.

Ethical approval was obtained from Al Neelain Ethical Committee and written informed consents were obtained from the patients or their parents in case of children before being enrolled in the study. The results of the analyses (cytogenetic, hormones, SRY mutation analysis, hormonal profile etc) were used for clinical diagnosis and were offered free of charge for all patients participating in the study. In addition to the medical history and the physical examination, all patients had an ultrasound and cytogenetic analysis. Hormonal, and molecular analysis and laparoscopic examination whenever it was possible.

Methods

Medical history and physical examination

Physical examination was carried out by a senior physician, being either urologist, pediatric surgeon, obstetrician, or pediatrician, with special emphasis on the palpability and symmetry of gonads, size of phallus in cm, hypospadias or sinus urogenital, pigmentation of genital and areolas area, and blood pressure. Most of the adult patients had psychological assessment followed by preoperative psychotherapy for cases requiring sex reassignment.

Samples collection

About 4 ml of venous blood were collected from each patient under complete aseptic condition. Instantly, 2

ml were placed in a sterile container that contained sodium heparin and used for cytogenetic analysis, the other 2 ml were kept in EDTA container for extraction of the DNA, 3 ml were taken to obtain the serum later for hormonal analysis.

Cytogenetic analysis

Lymphocyte culture

One ml of peripheral blood was sampled from each patient under aseptic conditions and transferred to the cytogenetic laboratory within 2 hours. All samples were processed for culture by adding 8 drops of blood to 10 ml of McCoy's 5A Modified Media (Sigma®), that has been supplemented with L-glutamine, penicillin (100 IU/mL), streptomycin (200 µg/mL), 25% fetal bovine serum (Sigma®), and 3.4 mL phytohemagglutinin (10 µg/mL) (Sigma®), and incubated in 5% CO₂ at 37 °C incubator for 72 hours.

Culture harvesting

All cultures were harvested after 72 hours, by adding 100 µg/ml of Colcemid (10 µl/ml) (Sigma®), 30 mins prior harvesting to arrest the cells (lymphocytes) in metaphase. After hypotonic shock in 0.075 M KCl, the cells were fixed four times in methanol: acetic acid (3:1) four times.

Slide preparation

Cells suspension was centrifuged at 1300 rpm for 10 min before removing the supernatant and resuspended in approximately 0.5 ml of fresh fixative (3:1 methanol: acetic acid). 1-4 drops of cell suspension were placed on a clean dry glass slide. The quality and spreading of chromosomes were assisted under a phase contrast microscope after that 2-4 slides were prepared for each patient.

Slide staining and analysis

The slide were kept overnight in the oven at 60 °C so as to obtained slide-aging. The slides were immersed in a buffer solution (2XSSC) and kept in a water bath at 60 °C for 2-3 h. After that the buffer solution was poured off and the slides were washed repeatedly with running tap water, air-dried for 1 hour before the staining. G-banding was obtained using Wright's stain and for each case, 5 to 25 metaphases were analyzed using CytoVision system, Applied Imaging®. The clonality criteria and the

karyotypic descriptions were done according to the International System for Chromosomal Nomenclature (ISCN) (1995) recommendations (Mitelman, 1995).

Molecular analysis

DNA extraction

DNA was extracted from blood samples collected in EDTA containers using Wizard Genomic DNA Purification Kit Promega®. DNA samples were kept at -20 °C until PCR was applied.

Polymerase chain reaction (PCR)

PCR amplification was performed using primer for SRY gene. In brief, SRY gene was amplified PCR from the DNA of the patients, as well as from the fertile XX female and fertile XY male controls. DNA Primers sequence and temperature used for DNA (Table 1)

The PCR mixture for every sample consisted of 1.0µL of genomic DNA, 0.2 µL (1.0 U) of Taq polymerase, 3.0 µL of each primer, 1.0 µL dNTPs, 1.5 µL MgCl₂, 12.8µL H₂O and 2.5µL PCR buffer in a final volume of 25 µl.

The PCR conditions were 5 min at 95 °C for pre-heating, 35 cycles of 94°C for 20 seconds (denature), 61°C for 45 seconds (annealing) and 72°C for 1½ min (extention), and 72°C for 5 min. Reaction products were electrophoresed on 1.5% agarose-TBE gels containing 0.5 µg/ml Ethidium bromide (for staining) and documented with gel electrophoresis. Hyper ladder 100 bp has been used as a marker.

Hormonal analysis

Measurements of serum level for hormones (LH, FSH, testosterone, estrogene, progesterone, cortisol, and prolactin) were performed in selected cases by either Radio Immunoassay Assay (RIA) or Immunoradiometric Assay (IRMA) using commercial kits (BioSource Europe S.A®).

Results

Of the 70 intersex patients enrolled in the present study 18 were reared as males (26%); age ranging between 49 days and 32 years (mean 16 years), 52 as females (74%); age ranging between 7 days and 34 years (mean 17 years). The age groups most commonly involved were those patients above 17 years representing 40% of all cases, followed by those

with age less than 2 years representing 33%, and those with age ranging between 2 and 17 years accounting for 27% of all intersex cases.

Tribal origin analysis indicated Jaaliyin tribe as the most common Sudanese tribe, accounting for 19%

Table 1 DNA primers sequence and temperature used for SRY gene analysis

| Primer | DNA sequence (5' to 3') | Temp (°C) |
|---------|-------------------------|-----------|
| Forward | Tacagccatgcacagagag | 60 |
| Reverse | Taagtgctagctggtgct | 60 |

followed by Dar-Hamed and Shaigiya; each accounts for 4% of all intersex patients.

Half of the patients have been referred due to genital ambiguity, other complains such as primary or secondary amenorrhea, failure to thrive, and short stature were also reported.

Psychological assessment revealed that, 13 patients (19%) were satisfied with their sex of rearing, whereas 5 patients (6%) were not satisfied, 16 patients (23%) could not decide, and the remaining 36 patients (51%) were children and thus no assessment has been performed.

History obtained revealed first degree of parental consanguinity in 30 (43%) of the cases, 3 cases (4%) were from second degree parental marriage, 7 cases (10%) had no parental consanguinity, and no information were available regarding the remaining 30 patients (43%).

Out of the 70 patients included in the present study final clinical diagnosis was reached in 55 patients. Of those, 23 patients were diagnosed as male pseudohermaphrodites, 2 patients as testicular feminization syndrome, 14 patients as complete gonadal dysgenesis syndrome, 8 patients as female pseudohermaphrodites, 6 patients as true hermaphrodites, and 2 patients as Smith-Lemli-Opitz syndrome, and Down's syndrome that associated with ambiguity. The clinical diagnosis on the remaining 15 was still under controversial till the end of the present study (Table 2).

Discussion

The birth of a newborn with disorders of sexual development (DSD) often comes as a

shocking experience for the parents especially in developing countries such as Sudan in which ambiguous genitalia often associated with DSD goes unnoticed by the delivery attendance in the complete absence of other qualified senior health personal. The terrible scenario continuous further if the new birth baby turn to be a

Table 2 Diagnoses of intersex cases involved in the study

| Diagnosis | Cases | % |
|--|-------|----|
| Male Pseudohermaproditism | 23 | |
| Complete androgen insensitivity syndrome (Testicular feminization syndrome) | 2 | 3 |
| Others | 21 | |
| Complete Gonadal Dysgenesis | 14 | |
| Turner's Syndrome | 9 | 2 |
| Swyer Syndrome | 1 | 0 |
| Others | 4 | |
| Female Pseudohermaphroditism | 8 | 1 |
| Congenital adrenal hyperplasia | 7 | 1 |
| History of androgen-like drug. | 1 | 1 |
| True hermaphroditism | 6 | 9 |
| Female Pseudohermaphroditism or True hermaphroditism | 5 | 7 |
| Male Pseudohermaphroditism or True Hermaphroditism | 3 | 4 |
| Dysmorphic features with ambiguous genitalia. (Smith-Lemli-Optiz syndrome and Turner syndrome) | 2 | 3 |
| Under Controversy | 10 | 14 |

Note: Turner's syndrome put into two categories, those complete gonadal dysgenesis and dysmorphic features (a patient diagnosed as Turner with Down's syndrome).

malepseudohermaphrodites and, therefore, wrongly assigned as female and thus inevitably soon undergo female genital mutilation FGM; a drastic criminal act persisting in Sudan with extremely high incidence reaching 89% of females in northern Sudan (Magoha and Magoha, 2000) although it was outlawed since 1946. FGM is performed often in male pseudohermaphrodites leading to lifelong felony. More effort should be exerted to enforce the band of this brutal act in those patients that leads leastly to complete mask of the clinical disease picture until puberty.

The importance of the present study was not only to describe the clinical and genetic profile of the disease in DSD Sudanese patients, but also to shed light on the stigma illness that till now has been individually and inappropriately managed. Thus the real achievement of the present study was the establishment of a multidisciplinary group (Sudanese intersex working group) capable of providing high-quality diagnostic and management service for patients with DSD in Sudan by the end of the study.

In this study, two patients were not satisfied with their reared sex and one patient had a history of suicidal attempt. According to the diagnosis work-up, they have been diagnosed as male pseudohermaphrodites. Unfortunately, the patients was assigned, unjustified, as females so the sex assignment was either irrational or it was based on mistaken clinical diagnosis. One patient underwent the irreversible catastrophe of penis amputation and bilateral gonadectomy during FGM that performed during childhood, all led to massive anatomical distortion and put huge challenges on any future sex reassignment. Five cases represent the inevitable scenario when a male pseudohermaphrodites baby was mistakenly assigned as female by the birth attendance. All those cases were misdiagnosed and hence wrongly assigned and grown up as females and experience female genital mutilation resulting in complete or partial amputation of the penis. The psychological assessment of those patients was consistent with the true sex of the patients showing clear cut and strong male orientation. Sadly enough, they presented at adulthood, meaning that they have been trapped in the social stigma of the disease for quite long time and this may explain their voluntarily seeking help from the Sudanese Intersex Working Group.

In spite of the female genital mutilation that performed wrongly in one of the cases, preoperative hormonal therapy (testosterone) and intense reconstructive surgery managed to restore the anatomy and the physiological function, in fact the patient managed to restore his gender role so quickly and today he is a happy married male (Figures A, B, C,

D, E, F). Although, the SRY gene is widely considered as the gene for determining sexual identity, many reports have discovered differences in genetic expression that happen before the SRY gene becomes active during development. It is possible that male-female brain differences start developing before SRY gene starts changing genitals development (Vilain and McCabe, 1998; Dewing et al., 2003).

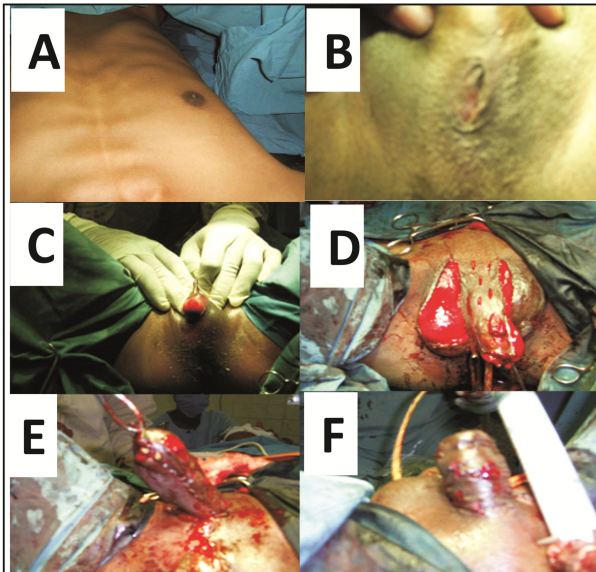


Figure 1 A: Absent breast; B: Circumcision type 4, palpable rounded structure in the Lt. side (below the skin), approximate 4 cm palpable Phallus superiorly and below the skin; C-F: Reconstructive surgery.

Although the present study includes 70 intersex patients, one would expect that many patients failed to come forward, either due to the social stigma or difficulties to access medical care facilities at least for people living in rural areas. In some cases misconception and confusion of the patients or the parents may contribute to discourage DSD patients from seeking treatment and medical advice especially in low class non-educated societies. The present study thus incriminates the cultural and social barriers involved in this sensitive issue. However, the study included patients with various cultural, social, and geographical regions suggesting that the agony among the patients especially the adult ones was so strong forcing them to come forward voluntarily.

The work-up of DSD needs several specialized diagnostic tests that include hormonal and enzymatic

profile, cytogenetic, and molecular analysis, imaging studies, and histopathology examination of gonadal biopsies. The process of diagnosis is expensive and time consuming. In addition to that some diagnostic tools were not available. All these hinder the diagnosis process leading to loss of some patients before reaching the final diagnosis.

According to the present study male pseudohermaphroditism represented the most common sexual disorder accounting for 33% of all intersex cases, followed by complete gonadal dysgenesis (20%), and then female pseudohermaphrodite (11%).

Our results may reflect miss- or delay-diagnosis of congenital adrenal hyperplasia that lead to death of undiagnosed child. A baby with congenital adrenal hyperplasia is brought to district clinic at late stage complaining of diarrhea and vomiting, seen by medical assistant that misses the feature of genital ambiguity and treat the child as gastroenteritis.

Circumcision of intersexed child is prohibited by Islam. This will lead us to shed the light on female genital mutilation, which is usually carried out by non-medical individual and still being mandatory among different societies and tribes especially in rural areas. Generally, circumcision increases complexity of diagnosis of DSD, mainly if the child is reared as a female and being extremely circumcised, i.e., type 3 or 4 (WHO Technical Working Group, 1996), or sometimes part of penis is amputated. Out of 70 patients included in the present study 23 patients (33%) were diagnosed as male pseudohermaphrodites. Of those 23 patients 8 were raised as males and 15 raised as females and thus underwent female genital mutilation. All patients (aged 49 days - 31 years), except those had female genital mutilation, presented with unilateral and/or bilateral unpalpable testes and small phallus ranged between 1 to 2.4 cm. Abdominal ultrasound revealed absence uterus and in cases with undescended testicles no gonads could be identified specially in young patients. Chromosomal analysis in all cases revealed 46, XY karyotype. Hence, evaluation of a child with ambiguous genitalia may become more complicated. The anatomical features of the external genitalia are extremely changed, thus, it will lead to more difficulty in assigning the child sex and also more psychological impairment. In addition, mythologies seem to play important negative role in

some rural areas of Sudan. Some tribes have specific rituals; the so called Kujur (medicinemane) has the role and the authority of sex assignment which may be decided regardless of the baby's real sex of normal babies. Moreover, some male-children are being castrated at early age to feminize them; this practice has an economic impact since those castrated children would increase the number of females working in agricultural field [El-tayib, 1970].

Finally, multidisciplinary approach that involves neonatologists, geneticists, endocrinologists, pediatric surgeons, experienced radiologists, psychiatrists and

psychologists, pathologists, and molecular biologists remains the best approach for diagnosis and management of DSD patient. Involvement of individuals other than health personal (lawyers, social workers, community leaders and religious men) is extremely important for the process of proper management and post sex and/or gender assignment period.

This figure 1 showing a patient with 46,XY DSD (Male *pseudohermaphrodite*); (A) Absent breast and secondary sexual characteristics; (B) External genitalia mutilated into female circumcision type 4; (C) palpable rounded structure in the Lt. side (below the

skin), approximate 4 cm palpable Phallus superiorly and below the skin; (D) The remaining Phallus freed for penis reconstruction and the Lt. testis brought down; (E and F) Final result of reconstruction of the external genitalia resulting in 5 cm penis and bilateral testicles.

References

- Arboleda V.A., Lee H., Sanchez F.J., Delot E.C., Sandberg D.E., et al., 2013, Targeted massively parallel sequencing provides comprehensive genetic diagnosis for patients with disorders of sex development. *Clinical Genetics*, 83: 35–43.
<http://dx.doi.org/10.1111/j.1399-0004.2012.01879.x>
- Lee P.A., Houk Christopher P., Ahmed S., Faisal Hughes, Ieuan A., 2006, In collaboration with the participants in the International Consensus Conference on Intersex: Consensus statement on management of intersex disorders. *Pediatrics*, 118(2):e488-e500.
- Magoha G.A., Magoha O.B., 2000, Current global status of female genital mutilation: a review. *East African Medical Journal*, 77: 268-272.
- Marshall Graves J.A., May 2002, The rise and fall of SRY. *Trends Genetics*, 18(5):259-64.
[http://dx.doi.org/10.1016/S0168-9525\(02\)02666-5](http://dx.doi.org/10.1016/S0168-9525(02)02666-5)
- Mitelman F., An international system for human cytogenetic nomenclature, 1995, Recommendations of the International Standing Committee on Human Cytogenetic Nomenclature, Memphis, Tennessee, USA, October 9-13, 1994
- Vilain E., Dewing P., Shi T., Horvath S., 2003, Sexually dimorphic gene expression in mouse brain precedes gonadal differentiation. *Brain Research Molecular Brain Research*, 118: 82-90.
[http://dx.doi.org/10.1016/S0169-328X\(03\)00339-5](http://dx.doi.org/10.1016/S0169-328X(03)00339-5)
- Vilain E., McCabe E.R., 1998, Mammalian sex determination: from gonads to brain. *Molecular Genetics Metabolism*, 65: 74-84.
<http://dx.doi.org/10.1006/mgme.1998.2749>
- WHO Technical Working Group, 1996, Female genital mutilation. WHO